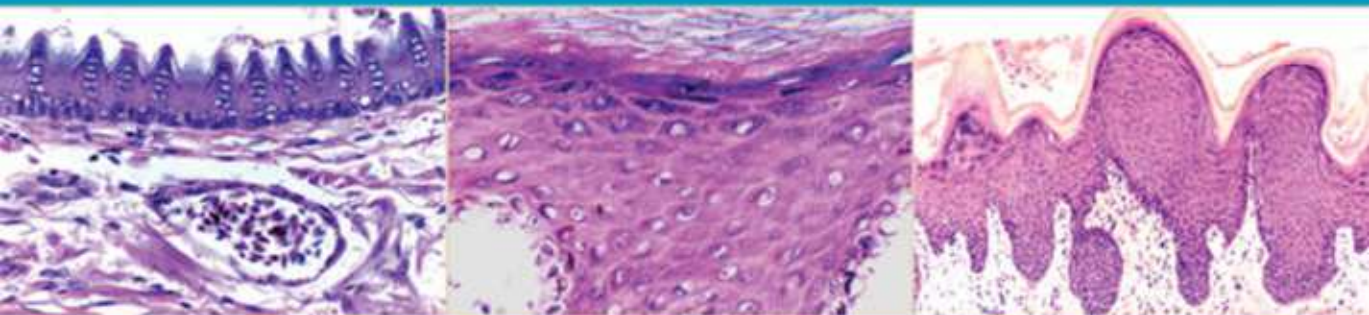


third edition

COLOR ATLAS of **VETERINARY HISTOLOGY**



WILLIAM J. BACHA, JR. AND LINDA M. BACHA

 **WILEY-BLACKWELL**

with website


COLOR ATLAS OF
**VETERINARY
HISTOLOGY**

Third Edition

COMPANION CD-ROM

This book is accompanied by a companion CD providing the more than 900 photographs digitally in an atlas interface with zoom capability. There are also interactive multiple choice study questions available for each chapter.

Note on access

Wiley publishes in a variety of print and electronic formats and by print-on-demand. Some material included with standard print versions of this book may not be included in e-books or in print-on-demand. If this book refers to media such as a CD or DVD that is not included in the version you purchased, please check for the material at <http://booksupport.wiley.com>. For more information about Wiley products, visit www.wiley.com

COLOR ATLAS OF VETERINARY HISTOLOGY

Third Edition

William J. Bacha, Jr., PhD

Professor Emeritus
Department of Biology
Rutgers University
Camden College of Arts and Sciences
Camden, New Jersey

Linda M. Bacha, MS, VMD

Assistant Professor of Biology
Department of Biology
Camden County College
Blackwood, New Jersey

 **WILEY-BLACKWELL**

A John Wiley & Sons, Inc., Publication

This edition first published 2012 © 2012 by John Wiley & Sons, Ltd.
First and Second editions © 1990 and 2000, Lippencott Williams & Wilkins

Wiley-Blackwell is an imprint of John Wiley & Sons, formed by the merger of Wiley's global Scientific, Technical and Medical business with Blackwell Publishing.

Registered office: John Wiley & Sons Ltd, The Atrium, Southern Gate, Chichester, West Sussex, PO19 8SQ, UK

Editorial offices: 2121 State Avenue, Ames, Iowa 50014-8300, USA
The Atrium, Southern Gate, Chichester, West Sussex, PO19 8SQ, UK
9600 Garsington Road, Oxford, OX4 2DQ, UK

For details of our global editorial offices, for customer services, and for information about how to apply for permission to reuse the copyright material in this book please see our website at www.wiley.com/wiley-blackwell.

Authorization to photocopy items for internal or personal use, or the internal or personal use of specific clients, is granted by Blackwell Publishing, provided that the base fee is paid directly to the Copyright Clearance Center, 222 Rosewood Drive, Danvers, MA 01923. For those organizations that have been granted a photocopy license by CCC, a separate system of payments has been arranged. The fee codes for users of the Transactional Reporting Service are ISBN-13: 978-0-4709-5851-3/2012.

Designations used by companies to distinguish their products are often claimed as trademarks. All brand names and product names used in this book are trade names, service marks, trademarks, or registered trademarks of their respective owners. The publisher is not associated with any product or vendor mentioned in this book. This publication is designed to provide accurate and authoritative information in regard to the subject matter covered. It is sold on the understanding that the publisher is not engaged in rendering professional services. If professional advice or other expert assistance is required, the services of a competent professional should be sought.

Library of Congress Cataloging-in-Publication Data

Bacha, William J.

Color atlas of veterinary histology / William J. Bacha Jr., Linda M. Bacha. – 3rd ed.
p. ; cm.

Includes bibliographical references and index.

ISBN-13: 978-0-470-95851-3 (hard cover : alk. paper)

ISBN-10: 0-470-95851-0 (hard cover : alk. paper)

1. Veterinary histology--Atlases. I. Bacha, Linda M. II. Title.

[DNLM: 1. Animals, Domestic--anatomy & histology--Atlases.

2. Anatomy, Veterinary--Atlases. SF 757.3]

SF757.3.B33 2011

636.089'1018--dc23

2011020601

A catalogue record for this book is available from the British Library.

Set in 10/11 pt Sabon by Toppan Best-set Premedia Limited

Disclaimer

The publisher and the author make no representations or warranties with respect to the accuracy or completeness of the contents of this work and specifically disclaim all warranties, including without limitation warranties of fitness for a particular purpose. No warranty may be created or extended by sales or promotional materials. The advice and strategies contained herein may not be suitable for every situation. This work is sold with the understanding that the publisher is not engaged in rendering legal, accounting, or other professional services. If professional assistance is required, the services of a competent professional person should be sought. Neither the publisher nor the author shall be liable for damages arising herefrom. The fact that an organization or website is referred to in this work as a citation and/or a potential source of further information does not mean that the author or the publisher endorses the information the organization or website may provide or recommendations it may make. Further, readers should be aware that Internet websites listed in this work may have changed or disappeared between when this work was written and when it is read.

**TO OUR PARENTS,
ANNA and BILL
LOLA and CHIP**

PREFACE TO THE THIRD EDITION

It is our hope that students and researchers will continue to find this atlas a useful resource. In this edition, we have expanded many of the beginning chapters that introduce the basic types of tissues to provide the user with a stronger foundation in histology. The glossary has been expanded, and other extras have been included that we hope will be valuable.

Once again, many thanks to all of those who have made the first and second edition of our atlas possible! We were able to prepare our page layouts for the third edition thanks to the scanner given to us

by Aunt Lila and Uncle Jack McKean and Lola and Chip Wood. Thanks to Jessie Bacha for proofreading our work, and to Tristan Bacha for keeping busy while we worked! We greatly appreciate the helpful suggestions from Professor Nancy Gartland and the students at the University Of Pennsylvania School of Veterinary Medicine, and from reviewers and users of the previous edition. Finally, thanks to Nancy Turner, Erica Judisch, Tracy Petersen, Erin Magnani, and all of the other people at Wiley-Blackwell for their role in the production of this edition.

PREFACE TO THE SECOND EDITION

We wish to thank those who have used the first edition for their suggestions. We believe the incorporation of many of these recommendations will make this edition even more helpful to the user.

To this end, we have updated the material for the second edition by scanning all of the original kodachromes and relabeling the art. We have added thirteen new photographs and have enlarged over one

hundred others. Four of the original black and white line drawings have also been redrawn. Also, a glossary of nearly 750 words has been added.

The style, format, and purpose of this edition remain essentially unchanged from the first edition. We continue to view the atlas as a useful, benchside reference for those interested in understanding and interpreting histologic and cytologic preparations.

PREFACE TO THE FIRST EDITION

Although we have written this atlas primarily to fulfill a need of the student of veterinary medicine, we believe that clinicians, private practitioners, and researchers will find it a useful reference for normal tissues and organs. Currently, students rely heavily, if not exclusively, on atlases of human histology for guidance in the laboratory. There are, of course, similarities between organs and tissues of domestic animals and those of humans. There are also differences, however, and these are rarely encountered in atlases dealing specifically with human histology.

Our aim has been to compare the histologic structure of organs in a variety of domestic animals. We have used representative examples in instances where tissues and organs from different animals share a common structure. Wherever differences exist, we have tried to provide examples that are characteristic of a particular group of animals. Our selection of animals includes the dog, cat, horse, cow, sheep, goat, pig, and chicken because they are most frequently referenced in veterinary school curricula.

All photomicrographs and drawings are original. Some drawings were done free-hand, while others were made with the aid of a camera lucida. Light microscopy and colored photomicrographs have been used exclusively. We have chosen color rather than black and white because of its correspondence to stained preparations. With the exception of the few histologic preparations loaned to us by generous donors or purchased from a dealer, slides were prepared by the authors. Fresh organ samples were obtained from a slaughterhouse or from animals that were euthanized for various reasons. With the exception of smear preparations (blood, bone marrow, and vaginal), mesenteric spreads, ground bone, and a single plastic section, slides were prepared using the paraffin method. All slides were stained with hematoxylin and eosin unless otherwise noted. Magnifications of photomicrographs are total magnifications (enlargement of photograph \times objective \times projector lens). Throughout the atlas, hollow structures, for example, blood vessels, kidney tubules, and alveoli, are usually identified by labeling the lumen of the structure.

ACKNOWLEDGMENTS FROM THE FIRST EDITION

Help is often just around the corner. Dr. Henry Stempen, whose office was down the hall from ours at Rutgers University in Camden, New Jersey, stopped by one day and volunteered his artistic talents. We'd like to thank him for his excellent pen and ink drawings of various animal parts, which are somewhat removed from the fungi he usually draws. Our gratitude also to Ms. Kathleen Carr for her secretarial services. Special thanks are extended to Dr. Edward Zambraski, Ms. Kathleen O'Hagan, and Ms. Gail Thomas of Cook College, Rutgers University, for making fresh porcine material available to us, and to Dr. Barry Jesse and Dr. James Harner for supplying us with sheep parts.

Without the unqualified use of the facilities and equipment of the Biology Department of Rutgers, our tissue processing and photomicrography could not have been accomplished. Our special thanks to the department for this courtesy.

This book would never have had a beginning were it not for the generosity of Dr. Leon Weiss, Department of Animal Biology, University of Pennsylvania School of Veterinary Medicine, who invited us to teach in the veterinary histology laboratory and kindly allowed us access to the slide collection and facilities of the depart-

ment. We would also like to express appreciation to the following individuals from the University of Pennsylvania School of Veterinary Medicine: Mr. Richard Aucamp and Mrs. Kathy Aucamp, who provided us with specimens, slides, advice, and assistance in a variety of other ways; Dr. Mark Haskins for kindly making available fresh canine and feline material; Dr. John Fyfe and Dr. Vicki Meyers-Wallen for supplying us with canine vaginal smears; Dr. and Mrs. Loren Evans and Dr. David McDevitt for lending us reference material; Dr. Peter Hand and Ms. Graziella Mann for providing material on the nervous system; and Dr. Helen Acland, Dr. Linda Bachin, Mr. James Bruce, Dr. Sherrill Davison, Ms. Dawn Dowling, Dr. Robert Dyer, Dr. Robert Eckroade, Dr. George Farnbach, Dr. David Freeman, Dr. Wendy Freeman, Dr. Alan Kelly, Mr. Joseph McGrane, and Dr. Mary Sommer for their time and consideration in helping us to obtain tissue specimens.

We are grateful to Dr. Carol Jacobson and the Department of Anatomy of the Iowa State University College of Veterinary Medicine for providing valuable slide preparations and text material.

Our gratitude is also extended to Hill's Pet Products, Topeka, Kansas, and

Pitman-Moore, Inc., Washington Crossing, New Jersey, for their generous financial assistance.

Many thanks also to: Dr. Caroline Czarnecki of the University of Minnesota, College of Veterinary Medicine, for providing copies of her informative laboratory guide; Dr. Deborah Ganster, Dr. James Lawhead, Dr. Virginia Pierce, Dr. Maria Salvaggio, Dr. Barbara Strock, and Dr. Cindi Ward for assisting us in obtaining tissue samples; Mr. Jeff Bringhurst, Bringhurst Brothers, Tansboro, New Jersey, for allowing us access to fresh large animal material; the Longenecker Hatchery, Elizabethtown, Pennsylvania, for providing chicken specimens; Ms. Susan Ulrich, Cornell University Press, for lending us a difficult-to-obtain reference; the helpful people at Optical Apparatus Company Inc., Ardmore, Pennsylvania, for supplies and for assistance with equipment for the microscope; and Mr. Charles Behl and Mr. James Durso of Webb and

Company Inc., Cherry Hill, New Jersey, for their courteous service and helpful advice.

We are indebted to Mr. William J. Bacha, Sr., for building a super light box for us, and to Mr. Thomas H. Wood, Jr., for providing black and white prints of our photomicrographs, which saved us countless hours of drudgery in the darkroom. Thanks to Barbara Frasco, Esq., for her helpful advice. Our hats are off also to Snuff, Chew, Chapter Seat, Angel, Clyde, and all the other animals for their participation.

We also wish to extend our gratitude to all at Lippincott Williams & Wilkins whose efforts helped bring this second edition into being. We are especially grateful to Carroll C. Cann and Jennifer D. Weir for their professional advice, courtesy, and assistance.

William J. Bacha, Jr.
Linda M. Bacha

CONTENTS

1	General Principles of Histology	3
2	Epithelium	11
3	Connective Tissue Proper and Embryonic Connective Tissue	19
4	Cartilage	27
5	Bone Tissue	31
6	Blood	41
7	Bone Marrow	53
8	Muscle Tissue	57
9	Nervous System	65
10	Cardiovascular System	77
11	Lymphatic System	89
12	Integument	105
13	Digestive System	139
14	Urinary System	183
15	Respiratory System	195
16	Endocrine System	211
17	Male Reproductive System	225
18	Female Reproductive System	243
19	The Eye	267
20	The Ear	283
	Glossary	291
	Bibliography	309
	Index	311

COLOR ATLAS OF
**VETERINARY
HISTOLOGY**

Third Edition

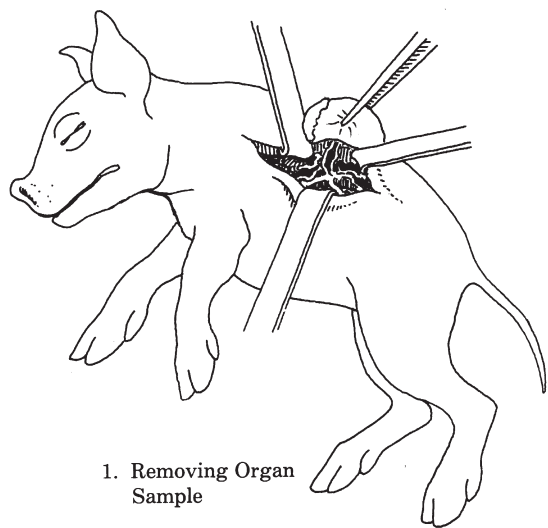
GENERAL PRINCIPLES OF HISTOLOGY

PREPARATION OF HISTOLOGIC SECTIONS

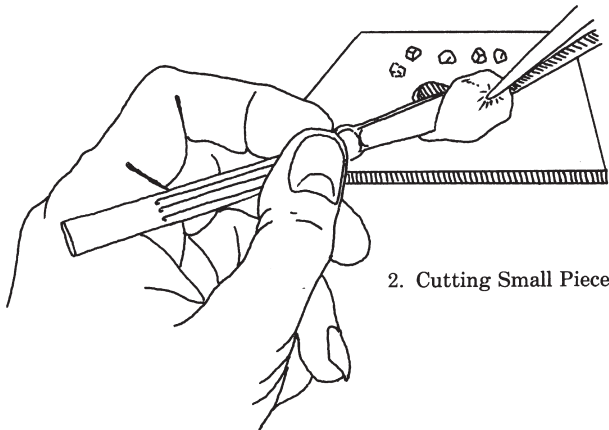
A histologic section is a thin slice of tissue, varying, usually, from 0.5 to 10 or more micrometers (μ) thick. In preparing such a section, a piece of tissue is either infiltrated with a supporting medium or frozen and is then cut with an instrument called a microtome. Sections obtained from tissue infiltrated with plastic can be as thin as 0.5 μ and show superior detail. Excellent preparations as thin as 2 or 3 μ also can be made from tissue infiltrated with paraffin-based embedding media. Sections are affixed to microscope slides and colored with one or more stains to increase the visibility of various cellular and intercellular components.

Schematically, Figure 1.1 outlines various steps involved in producing a stained histologic slide using the paraffin procedure. After being removed from an animal, a tissue or organ is cut into pieces. These pieces are placed into a fixative such as buffered formalin or Bouin's, which, ideally, preserves normal morphology and facilitates further processing. After fixation, the specimen is dehydrated by transferring it through a series of alcohols of increasing concentrations to 100% alcohol. Next, it is placed into a substance such as xylene or xylene substitute, which is miscible with both 100% alcohol and paraffin. This intermediate step (called clearing) is essential before infiltrating the dehydrated tissue with paraffin because alcohol and paraffin do not mix. During infiltration, melted paraffin completely replaces the xylene. This procedure is done in an oven at a temperature just above the melting point of the paraffin. When infiltration is complete, the specimen is transferred to an embedding mold of fresh paraffin, which is allowed to harden. Then the mold is removed and excess paraffin is trimmed away.

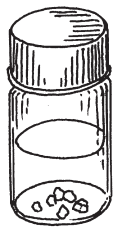
The block of paraffin is then secured to the microtome and oriented appropriately with respect to the knife. With each revolution of the microtome handle, the specimen moves through the blade and a section of the desired thickness is produced. Each successive section adheres to the preceding one, forming a continuous ribbon. Subsequently, one or more sections are carefully separated from the ribbon and transferred to the



1. Removing Organ Sample



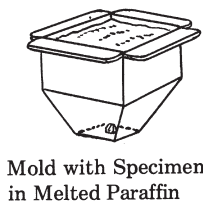
2. Cutting Small Pieces



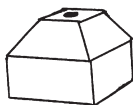Fix

↓
Dehydrate
↓
Clear
↓
Embed

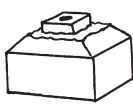
3. Preparing Specimens for Sectioning



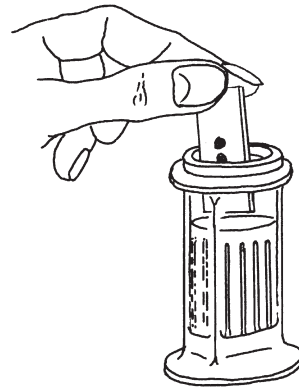
Mold with Specimen in Melted Paraffin



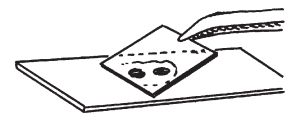
Paraffin Block Removed from Mold



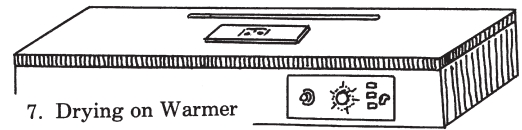
Trimmed Block



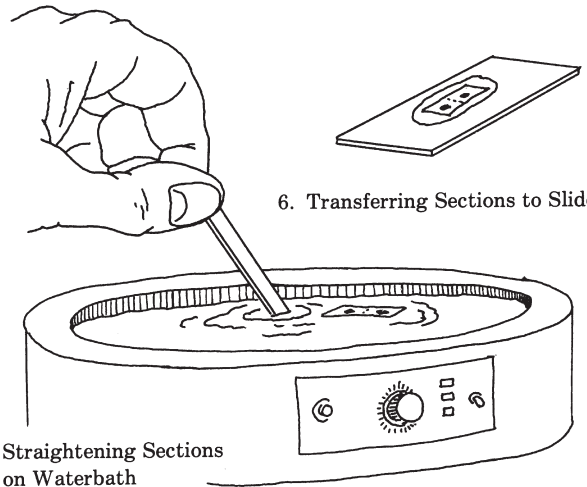
8. Staining



9. Coverslipping

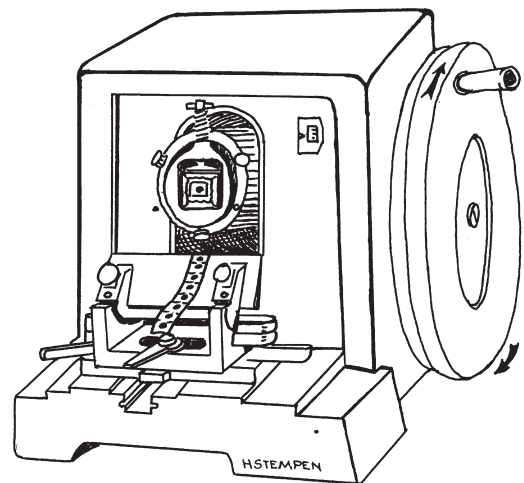


7. Drying on Warmer



5. Straightening Sections on Waterbath

6. Transferring Sections to Slide



4. Sectioning with Microtome

Figure 1.1. The various steps involved in producing a histologic slide using the paraffin method.

surface of warm water in a waterbath. This softens the paraffin and flattens the section, eliminating wrinkles. The flattened section is floated onto a slide, which is then placed on a warming table. As the preparation dries, the section adheres to the surface of the slide.

Next, the paraffin is removed with xylene or another appropriate solvent and the specimen is rehydrated. It is then stained, dehydrated, cleared (made transparent) with xylene, covered with a resinous mounting medium, and topped with a cover-slip.

Various stains are available to the histologist. Hematoxylin and eosin (H&E) is a frequently used combination of stains. Hematoxylin imparts a purple color to substances, but must be linked to a metallic salt called a mordant before it can function effectively. This combination, called a lake, carries a positive charge and behaves as a basic (cationic) stain. The lake combines electrostatically with negatively charged radicals such as phosphate groups of nucleoproteins. Substances that become colored by a basic stain are said to be basophilic. Methylene blue, toluidine blue, and basic fuchsin are basic stains. Unlike hematoxylin, these stains have molecules that carry a positive charge of their own and do not require a mordant. Acidic (anionic) stains carry a negative charge and color cell or tissue components that bear positive charges. Eosin is an acid stain. It imparts an orange or red color to acidophilic substances. Other commonly used acid stains are orange G, phloxine, and aniline blue.

In addition to the widely used H&E staining procedure, numerous other stain combinations and techniques are available. Some are especially useful for identifying certain tissue elements. For example, trichrome procedures such as Mallory's and Masson's specifically stain collagenous fibers within connective tissue. Orcein and Weigert's resorcin fuchsin are stains used to color elastic fibers, providing a means of distinguishing them from other fibrous elements. Reticular fibers and nervous tissue components such as neurons, myelin, and cells of the neuroglia can be stained by procedures employing the use of silver. There are also special histochemical and immunohistochemical procedures that make possible the localization of various carbohydrates, lipids, and proteins found in tissue. Lastly, stains such as Wright's and Giemsa's (Romanovsky stains) are available for differentiating the various cells found in blood and bone marrow.

INTERPRETING SECTIONS

One must know the gross structure of an organ before a histologic section from it can be comprehended. It is also helpful to know how the section was cut, that is, whether it was a cross section (x.s.), a longitudinal section (l.s.), or an oblique slice through the organ. Was the cut made through the entire organ or only through a portion of it? Frequently, prepared slides are labeled indicating the particular orientation of the section. This is not important in an asymmetric organ such as the spleen or liver because their appearance would be unaffected by the direction of the cut. Conversely, the small intestine is radially symmet-

ric and its appearance is affected by the direction of the cut.

The three-dimensional structure of organs and their components also must be considered when examining a histologic preparation. Cells are three-dimensional objects differing in size and shape. For example, some are long and thin, some cuboidal, and others ovoid. They may have a random or specific arrangement within an organ. How they appear depends on their shape as well as how they were cut. Imagine how the spindle-shaped and tall columnar cells shown in Figure 1.2A would look if sectioned in various planes. Note that the nucleus may or may not be included in a particular cut through a cell.

The histologist examines multicellular structures having a wide variety of shapes. Some are hollow, some branch repeatedly, some open onto surfaces, etc. Figure 1.2, B and C, and Figure 1.3 show a variety of three-dimensional structures and how they would appear if cut at different levels. Examine these carefully. They will help you to understand situations you will encounter on actual slides.

HELPFUL HINTS

Be sure that the lenses of your microscope are clean before you begin examining slides. Use a piece of lens paper or a soft, clean cloth such as an old (but clean) linen handkerchief. If the lenses have been coated with oil or another substance, remove it using lens tissue moistened sparingly with a glass cleaner such as Windex. Slides also should be cleaned using a soft, lint-free cloth or tissue moistened with glass cleaner.

Every microscope should have a pointer in the ocular. This is usually supplied by the manufacturer, but can be made from a short piece of hair. The latter is cemented into place inside the ocular with a dab of quick-drying glue or nail polish. Without a pointer, it is not possible to accurately indicate an object in the microscope field for another observer.

Before beginning a session at the microscope, make sure that the fine-adjustment knob is near the middle of its range of rotation. If you do not, you may find that the knob is at the limit of its excursion when you are busily making observations. At that point, you must stop everything and correct it.

It is also a good habit to examine your slide with the unaided eye before placing it on the stage of your microscope. By doing so you will gain information about the gross aspects of the specimen and be more likely to center it properly over the light source. Centering is especially important for small specimens that might otherwise be difficult to locate. Also, make sure that you put the slide on the stage with the cover glass uppermost. If the slide is upside down, you will not be able to focus on it with the high-power lenses. Do not snicker. We have seen this happen often in the teaching laboratory!

It is always a good idea to start your observations using the lowest power objective available on your microscope. This is usually the 4x lens. The field of view will be

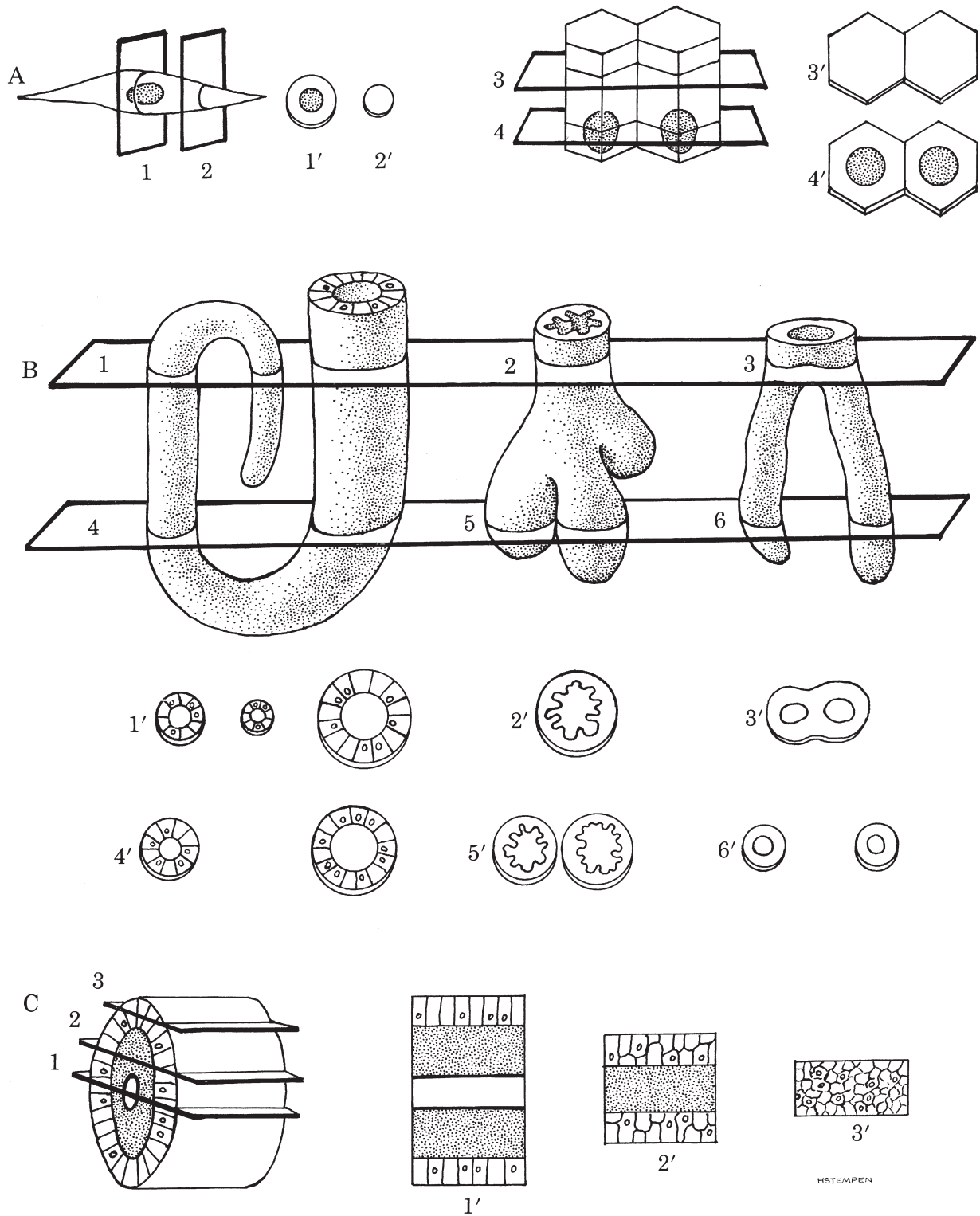


Figure 1.2. A. Slices, indicated by numbered planes, taken through two different types of cells would appear as identified by the prime numbers. Only if the plane of the cut passes through the nucleus will the latter be seen. B and C. Planes of section taken from different levels in four separate multicellular objects are illustrated. Note how the appearance of sections varies with the level of the cut.

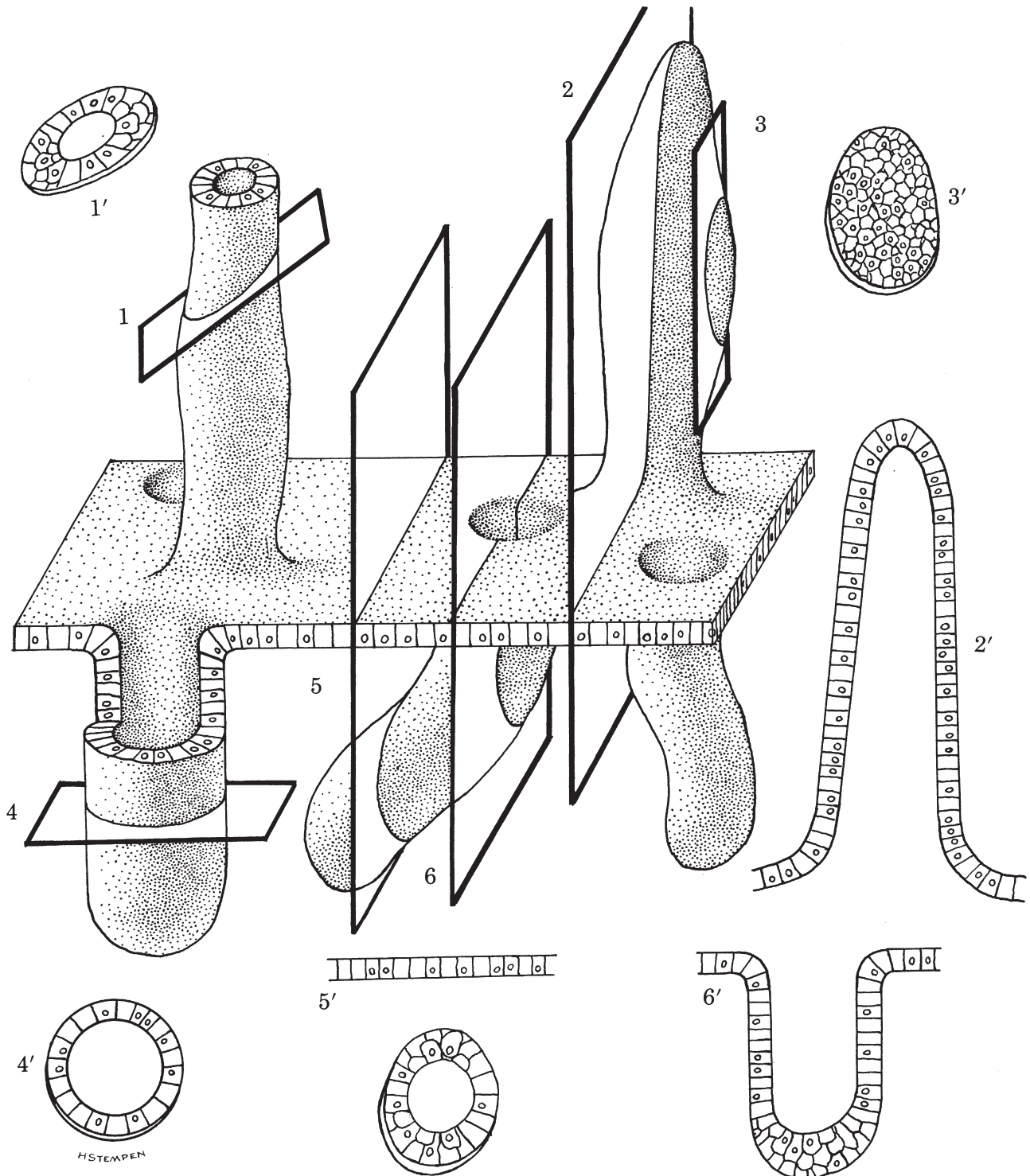


Figure 1.3. The prime numbers illustrate sections resulting from transverse (4), oblique (1), and longitudinal (2, 3, 5, 6) cuts made through a plate of cells bearing hollow projections (*above plate*) and invaginations (*below plate*). Plane 3 differs from the others because it passes only through the cellular wall of a projection, and not the lumen; therefore, section 3' appears as a plate of cells rather than a hollow structure. You should also be aware that structures may often appear unrelated to a surface or another object, when in fact they are. Compare planes 5 and 6 with sections 5' and 6', where continuity of the invagination with the surface is evident only in 6 and 6'. While not apparent from a single section, such continuity would be evident if an uninterrupted series of sections through the entire invagination were made and examined.

large, enabling you to locate regions of special interest more easily. When you locate something you wish to examine at a higher magnification, center the object in the middle of the field of view. Then, when you change to a stronger lens, the object should be somewhere in the field.

Binocular microscopes often have at least one ocular that can be adjusted to accommodate your vision. It is important that you adjust this properly if you want to have a comfortable, headache-free session at the microscope. Assuming that your microscope is of the binocular type and that it has at least one adjustable ocular, you should first bring the specimen into focus with the ocular that is not adjustable by using the fine-adjustment knob. When you have done this, focus the other eye using the adjustable ocular. Use of this procedure will ensure a proper focus for both eyes and prevent eye strain.

Yikes! After you turn on the microscope, you do not see any light as you look through the oculars! Before you replace the bulb, try the following:

- Check the light control lever or knob to make sure the light intensity is not set too low or turned down to zero.
- Check that the objective lens is clicked fully into position.
- Make sure that the plug is fitted properly into the electrical outlet and that the outlet is working.

Bright, even lighting is absolutely essential to effective microscopy. The best way to achieve this is to use Köhler illumination. This can be obtained with any microscope that is equipped with both a condenser aperture diaphragm (the one in the condenser) and a field diaphragm (the one in the light source). If you have such an instrument, proceed as follows:

1. Center the light source, using the directions you received with the microscope.
2. Open both the field and aperture diaphragms fully.
3. Raise the condenser to its uppermost position.
4. Place a specimen on the stage and focus on it using the $10\times$ objective.
5. Close the field diaphragm so that its leaves are clearly imaged in the field of view.
6. Center the image of the diaphragm by manipulating the condenser centering screws, then open the field diaphragm until its leaves disappear just beyond the edge of the field of view.
7. Remove an ocular and, while looking into the back aperture of the objective, close the aperture diaphragm completely and then open it until it is about 75% of being fully open.

You now have Köhler illumination. If you want to increase or decrease the light intensity, use the rheostat or neutral-density filters, but do not adjust the condenser aperture diaphragm or field diaphragm. If the aperture diaphragm is open to excess, the image will lack some contrast and be flooded with light. If it is closed too far,

there will be a loss of resolution and increase in contrast. This increase in contrast is often confused with sharpness or high resolution; this is a common error in microscopy. All of the above adjustments (except for centering the light source) must be made each time a different objective is used.

If your microscope lacks a field diaphragm, you will not be able to obtain Köhler illumination. You can still acquire good and useful lighting, however. Place a specimen on the stage, open the aperture diaphragm fully, and adjust the light intensity with the rheostat so that it is comfortable for your eyes. Be sure that the condenser is raised to its highest position, or close to it, when you do this. Now, remove an ocular and look at the back aperture of the objective. Close the aperture diaphragm fully and then open it until it is about 75% of being fully open. This will provide proper lighting for most purposes. If you should need more or less illumination, make adjustments only with the rheostat or neutral density filter; do not use the aperture diaphragm.

To get the most from a specimen, you must avoid being a passive microscopist, that is, one who finds an object and then stares at it admiringly without making further adjustments of the focus. Get into the habit of focusing continuously with the fine adjustment as you peruse a slide, because even though a tissue section may be only a few micrometers thick, the depth of field of the higher power objectives may be less than the thickness of the specimen. Therefore, if you do not focus repeatedly as you examine a preparation, you will certainly miss seeing structural detail that might be important to your work.

You might like to return to a particular location on your slide preparation at a future time. Remembering landmarks in the vicinity of the object of interest will aid you in locating the object later. A more expedient way of relocating structures is by using verniers, which are mounted on both the X and Y axes of the mechanical stage. A vernier consists of two parallel, graduated, sliding scales, one long and one short. The smaller scale is 9 millimeters (mm) long and is divided into 10 subdivisions (0 to 10). The larger scale is several centimeters (cm) long and is graduated in millimeters, for example, 0 to 80 or 100 to 160. To relocate an object on a slide, you must first center it in the microscope field. Once this has been done, you establish its location by reading each of the verniers (X and Y). For example, the 0 point on the small scale of the vernier on the X axis might be located somewhere between lines 42 and 43 on the larger scale (Figure 1.4). To determine its specific location, find the line on the small scale that coincides exactly with a line on the longer scale. Then count, on the smaller scale, the number of spaces between 0 and the point of coincidence. This number is your decimal point. In the example given (Figure 1.4), the

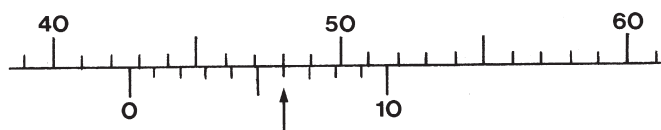


Figure 1.4. Small and large vernier scales.

decimal is 0.6 and you should read 42.6 as the vernier value. Do the same for the other vernier (Y) and record the numbers for both. In the future, if you want to return to the same location, simply secure the slide to the mechanical stage and move the stage controls until the verniers are adjusted to the numbers you previously recorded. These manipulations will have returned the slide to its former position, and the object you are looking for should be somewhere within the microscope field.

By knowing the approximate diameter of a red blood cell in a section, you can estimate the size of other tissue components. Therefore, it is useful to know that in tissue sections prepared by the paraffin method the average size of erythrocytes for each of the following animals is as follows:

Goat: 2.4 μ diameter (smallest erythrocytes of the domestic mammals)

Dog: 4.9 μ diameter (largest erythrocytes of the domestic mammals)

Chicken: 9.4 μ long

Each average value is based on a total of 20 to 30 cells that were measured from five different slide preparations of tissues embedded in Paraplast X-TRA (Monoject Scientific, Division of Sherwood Medical, St. Louis, MO 63103).

ARTIFACTS

Folds, knife marks, stain precipitate, spaces (where none belong), shrinkage, and air bubbles are examples of common imperfections seen in slide preparations. They were introduced during processing and are called artifacts. Figures 1.5 through 1.9 are examples of such artifacts.

Troubleshooting a blurred or cloudy image:

- If an image is cloudy or blurry, the oculars and/or objective lenses may need to be cleaned. To determine if an ocular needs to be cleaned, turn it as you look through the microscope. A dirty mark or smear will rotate if the ocular is not clean.
- If the image is still blurred, clean the objective lenses.
- Make sure the slide is resting on the stage properly and is right side up! Sometimes an image cannot be focused clearly because the slide is on the stage upside down!
- Are you using the oil immersion lens without a drop of oil on the slide?
- Be sure that the light source is not partially blocked by something, such as the electric cord or a filter holder below the stage.

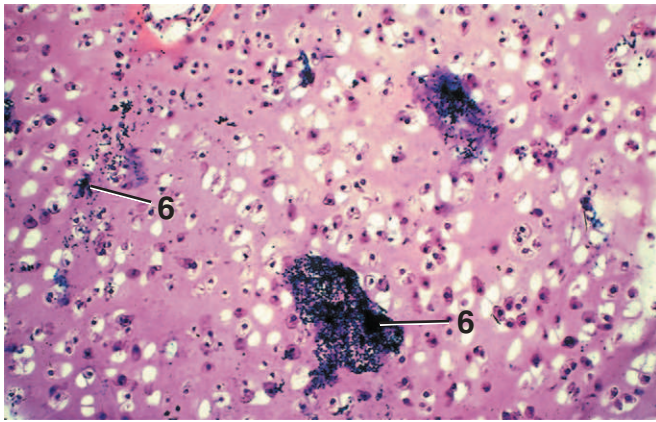


Figure 1.5 × 62.5

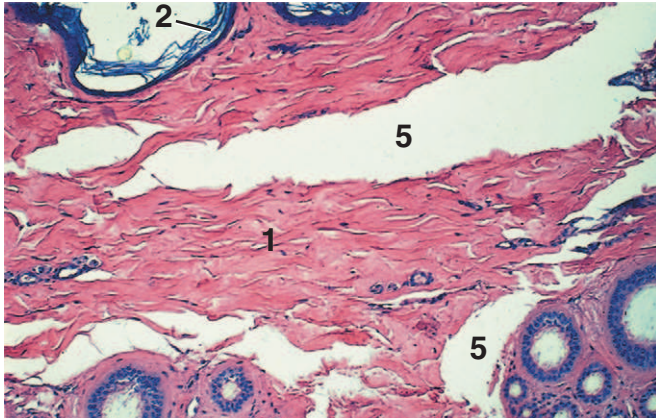


Figure 1.6 × 62.5

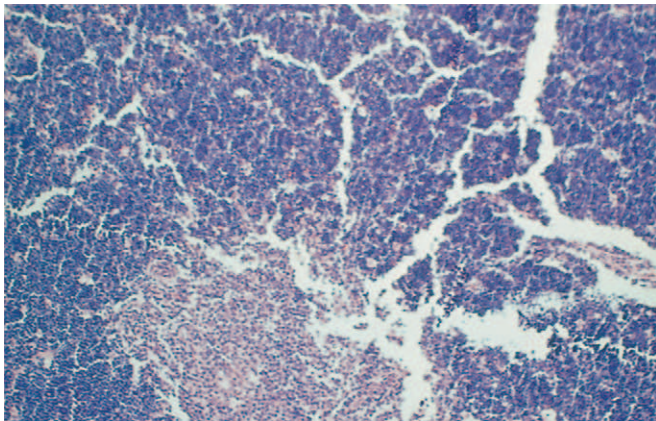


Figure 1.7 × 62.5

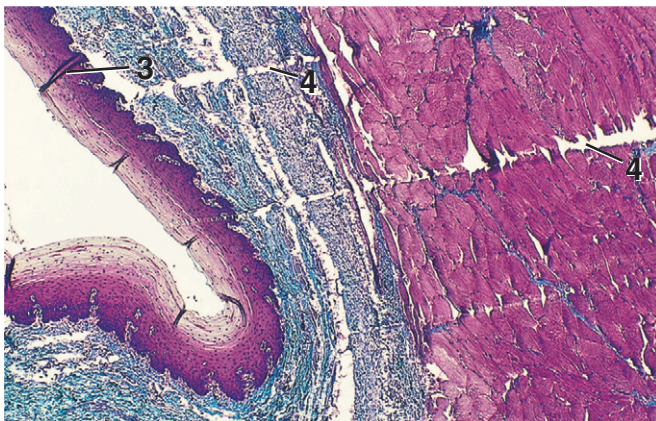


Figure 1.8 × 25

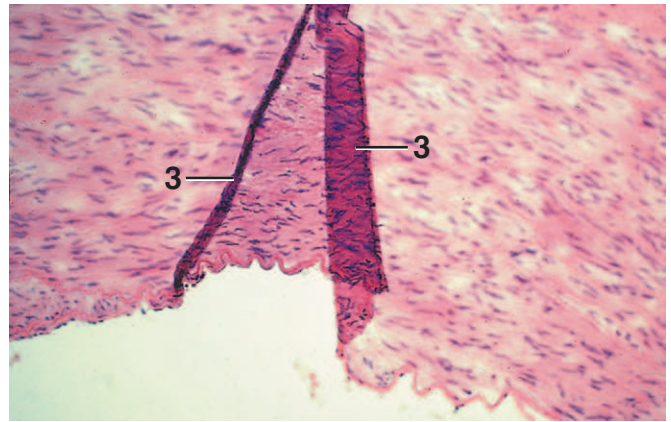


Figure 1.9 × 62.5

KEY	
1. Dermis	4. Knife mark
2. Epidermis	5. Separation artifact
3. Fold	6. Stain precipitate

Figure 1.5. Stain Precipitate, Cartilage, Dog. Occasionally, solutions accumulate precipitate that may stick to the surface of tissue sections during the staining procedure.

Figure 1.6. Separation (Space) Artifact, Skin, Dog. Tissues may be subjected to excessive pressures, tensions, or shrinkage during processing, resulting in separations within otherwise intact tissue.

Figure 1.7. Cracking Artifact, Thymus, Horse. Highly cellular tissues, for example, thymus, liver, pancreas, and spleen, often show numerous tiny cracks throughout. Also note that this specimen is not in sharp focus.

Figure 1.8. Knife Marks and Folds, Esophagus, Horse (Masson's). Knife marks (scratches) in the tissue section may be caused by defects in the microtome knife or by accumulations of debris on the knife edge. Folds occur when the tissue sections fail to spread properly on the surface of the slide.

Figure 1.9. Fold, Aorta, Pig. In a tissue section, folds are raised areas that frequently overlap. Note that portions of this picture are not in sharp focus.